

THE BRAIN CHANGES IN ELECTRICALLY INDUCED CONVULSIONS IN THE HUMAN*

BERNARD J. ALPERS, M.D.

AND

JOSEPH HUGHES, M.D.

[Philadelphia]

The widespread use of electrical convulsion treatment in the psychoses makes it essential to know what happens to the brain after such treatment. Apart from the academic interest in such observations, the matter is of great practical importance in view of the prolonged confusional state which develops after this treatment, suggesting that structural damage is produced by the treatment. For this reason the autopsy report of two cases which died following electrical convulsion treatment seems to be of particular importance.

CASE REPORTS

Case 1. M. C. Philadelphia State Hospital. Reg. No. 51103. Paranoid dementia praecox in a woman of 45. Electrical convulsion treatments, 62 in all, over a period of 5½ months. Numerous punctate hemorrhages in the cerebral cortex, medulla, cerebellum and basal ganglia. Areas of perivascular edema and necrosis.

History. The patient, a 45 year old Polish woman, was admitted to the Philadelphia State Hospital on December 31, 1940. Her past history was not important. She had come to this country 25 years previously, had married and made a good wife, she had two children, and was described as an introverted type of personality. Early in December of 1940 she became withdrawn, spent much time in prayer, and talked constantly to herself. She became delusional maintaining that the stars were leading her, and accused her husband of infidelity and of being the devil. She became abusive and quarrelsome. When admitted to the hospital she was agitated and talked constantly in a disconnected manner. She was suspicious, irascible, antagonistic, and clearly delusional, hallucinating both in the auditory and visual spheres. Her sensorium was clear.

Examination both physically and neurologically was negative. Urinalysis was normal. The Wassermann reaction of the blood and cerebrospinal fluid was negative. The blood sugar was 77 mg. per cent and the blood urea, 15 mg. per cent.

Course and Treatment. The patient continued unchanged for some time. She was resistive, restless, sometimes mute, and usually inaccessible. Electric shock treatments were started on February 3, 1941, about two months after her admission to the hospital. After a course of twelve generalized convulsions and six sub-convulsive treatments the patient appeared brighter, more alert, neat and tidy. She appeared also to have gained some insight but seemed clouded and her memory for events in the recent past remained poor. On the insistence of her family and against advice she was paroled May 17, 1941 but was returned to the hospital two days later after a suicidal attempt. She was again given forty-four more electric shock treatments and again became quieter. Thereafter her behavior varied: she was quiet at times, and at others disturbed. In October 1941, about seven months after her second admission, she developed signs of cardiac failure and bronchopneumonia. She died on October 17, 1941.

* From the Department of Neurology, Jefferson Medical College, Philadelphia, and the Institute of the Pennsylvania Hospital. Aided by a grant from the John and Mary R. Markle Foundation of the Pennsylvania Hospital.

Summary. The patient received in all sixty-two electric shock treatments from February 4, 1941 to July 26, 1941. Of these, forty-six were followed by general convulsions; the other sixteen resulted in no convulsive attacks. The treatments were given as a rule at intervals

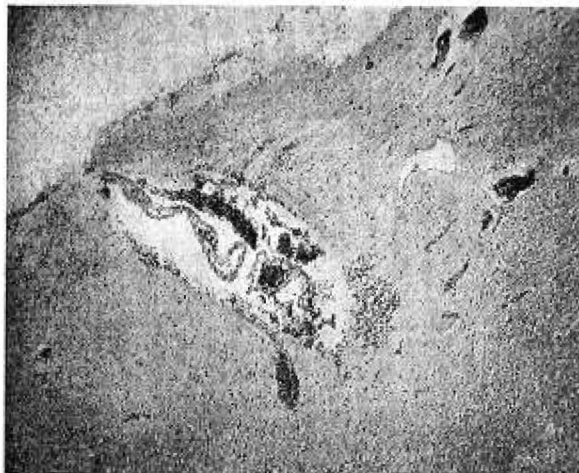


FIG. 1. An area of the cortex under low power showing hemorrhages in the subarachnoid space and in the subjacent cortex (case 1). Hematoxylin and eosin stain.

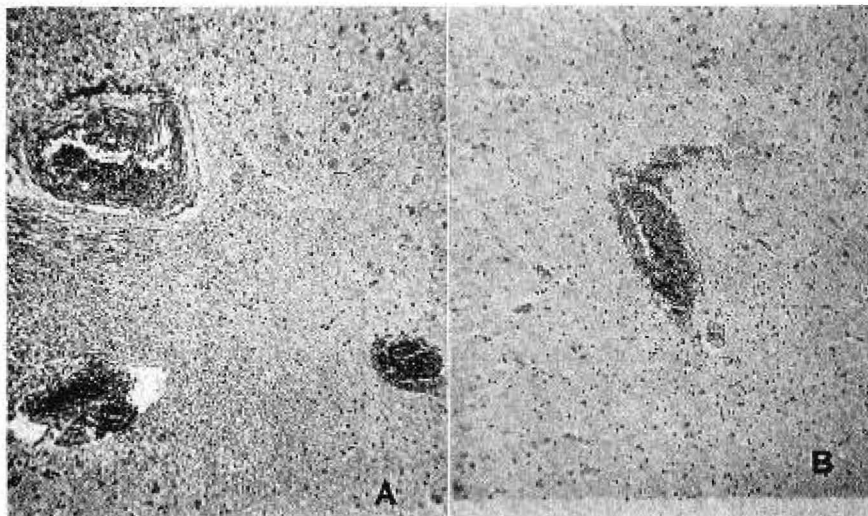


FIG. 2. Congestion of vessels and perivascular hemorrhages in the cerebral white matter (A) and well shown in B. Hematoxylin and eosin stain.

of two days, except for a few periods when they were spread out at five and seven days intervals. She died about two months after the last treatment.

Necropsy findings, general. Bronchopneumonia, osteomyelitis of the right index finger, edema of the left leg, marked fatty degeneration of the liver, and cholecystitis with cholelithiasis were found.

The brain weighed 1480 grams. The pia-arachnoid over both frontal lobes was markedly thickened and the anterior half of the sagittal fissure was obliterated by adhesions

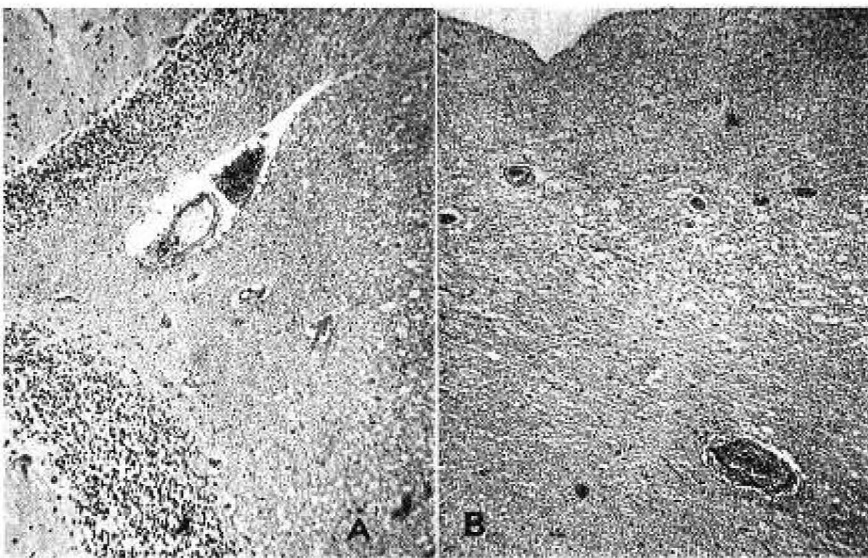


FIG. 3. A perivascular hemorrhage in the white matter of the cerebellum (A), and a similar hemorrhage at some distance from the ependyma of the lateral ventricle (B). Hematoxylin and eosin stain.

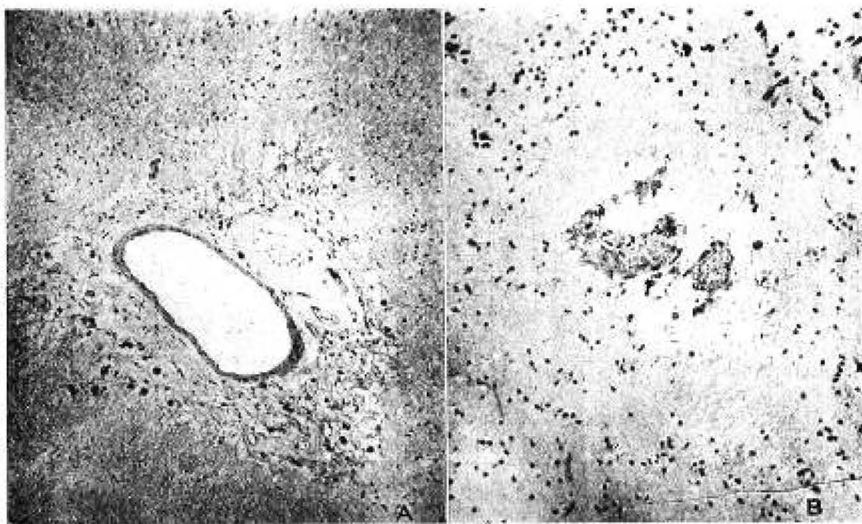


FIG. 4. A vessel in the white matter showing the rarefaction of the adjacent brain tissue and phagocytes containing hemosiderin (A), and similar but less marked changes (B). Hematoxylin and eosin stain.

between the two hemispheres. The blood vessels were normal in appearance. Coronal sections of the brain and brain stem revealed no abnormalities.

Microscopic anatomy. Histological examination was made of all parts of the cerebral cortex, the cerebellum, and brain stem by hematoxylin-eosin, cresyl violet, toluidin blue, and Weil stains. The *pia-arachnoid* was greatly congested, but the congestion was not generalized and varied in degree from one part to another. In a few areas free blood was seen in the subarachnoid space and in the subjacent *lamina zonalis* of the cerebral cortex (fig. 1). Generally speaking however, hemorrhage into the meninges was not prominent. The *cerebral cortex* and the white matter showed areas of focal congestion. Large portions remained unaffected, while others showed marked congestion of the arterioles, venules, and capillaries. In the congested areas mainly, and also in other portions of the cortex and white matter there were two striking changes: 1. perivascular hemorrhages of varying

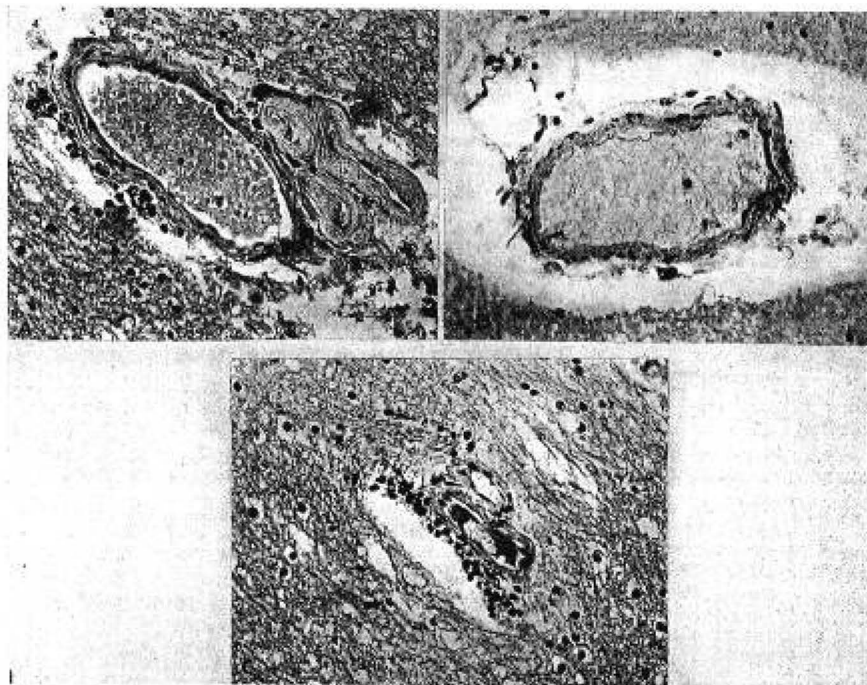


FIG. 5. A group of vessels in the white matter showing phagocytes containing hemosiderin around the vessels (A and B), and a cluster of glial cells in the adjacent brain tissue (C). Haematoxylin and eosin stain.

size and age (figs. 2 and 3). Some of these hemorrhages consisted of only a few red cells lying free in the perivascular space; others were large punctate hemorrhages. The age of the lesions varied. In some hemorrhages the red cells were well-preserved; in others hemosiderin was found free and within phagocytes, and in still others the red cells were in various stages of disintegration; 2. perivascular edema. Scattered areas of edema around the vessels were found chiefly in the white matter (fig. 4). The perivascular spaces in such instances were greatly dilated. Sometimes they contained phagocytes filled with hemosiderin. The brain tissue around the dilated perivascular spaces was rarefied and partially destroyed and in some places astrocytes were found forming a wall around such areas (fig. 5). These hemorrhages and areas of perivascular rarefaction and edema were found chiefly in the frontal and temporal areas. Hemorrhages were seen also in the thalamus, medulla, and cerebellum. In the floor of the fourth ventricle of the medulla was an enormously dilated vessel, with small punctate hemorrhages under the ventricular lining. An

occasional punctate hemorrhage was seen in the cerebellum. The nerve cells of the cerebral cortex were normal. The cortical arterioles were thickened.

Comment. The foregoing case is the first reported instance, so far as we know, of hemorrhages in the brain attributable to electrical convulsion treatment. That these findings are not the result merely of the large number of treatments given in this case is shown by the fact that lesions of varying age were found in the brain. In addition to recent hemorrhages, there were older hemorrhages; and what is more important, there were areas of perivascular edema and tissue destruction which represented old lesions and which might conceivably be regarded as the end result of the perivascular hemorrhages since some of them contained phagocytes with hemosiderin.

In any event, the importance of the case lies in that it offers a clear demonstration of the fact that electrical convulsion treatment is followed at times by structural damage of the brain. Whether all cases show a degree of damage similar to one recorded in our case, is not known. It would not be fair to assume that this is so, since few cases are subjected to the number of treatments which were given in this instance.

That the brain changes described in this case are not the mere result of over-treatment by electrically induced convulsions is shown by the findings in the second case in which death occurred five months after the last treatment, having received only a total of six treatments. The brain changes, while not as severe as in the first case, were of the same type and distribution. This case affords an opportunity therefore to study the effect of convulsive treatment as seen five months after the cessation of such treatment.

Case 2. R. K. Pa. Hospital No. 12536. Repeated attacks of manic-depressive psychosis. Six electric shock treatments. Death 5 months after cessation of treatment. Scattered areas of old perivascular hemorrhage, gliosis, fibrosis, and rarefaction chiefly in the white matter.

History. A widow, aged seventy-nine years, was admitted to the Pennsylvania Hospital for Mental Diseases for the third time on August 2, 1940, with a diagnosis of manic-depressive psychosis of a mixed type. The history of her previous physical health was unessential. She had passed through her menopause twenty-seven years previously at the age of fifty-two years. Her first episode occurred at the age of forty-six years and was characterized by agitation and depression. Recovery took place in ten months. The second attack developed one year after recovery from the first; it was similar in character and was followed by recovery in twenty months. The third episode occurred at the time of the menopause, developing three and one-half years after recovery from the second attack. The fourth attack took place at the age of sixty-three and again was characterized by agitation and depression. Recovery was followed by well being for twelve years when at the age of seventy-nine years she again became depressed and suicidal and was readmitted to the hospital.

Examination. There were bilateral cataracts with almost complete loss of vision in the right eye. The blood pressure varied between 150 and 180 systolic over 80 and 90 diastolic. Retinal arteriosclerosis was present. Apart from this, the examination revealed nothing significant. The laboratory data (urinalysis, blood count, blood chemistry) were all negative.

The patient was agitated, confused, depressed and delusional. A diagnosis of manic-depressive psychosis of a mixed type was made.

Course. The patient remained agitated, depressed and confused most of the time, with

periods of mild improvement being noted especially in the decrease of her depression. There was no material change in her condition, however, in the course of five months, and electric shock therapy was therefore contemplated. Her blood pressure was normal at this time: 130 systolic and 60 diastolic; the heart was not enlarged, and an electrocardiogram was negative. Electric shock treatment was, therefore, decided upon. She was given six electric shock treatments from January 15, 1941 to February 19th, 1941, following which she improved sufficiently to be allowed to leave the hospital for a cataract operation. She returned a month later once more in a depressed state. She received no more electric shock treatments at this time. Signs of cardiac decompensation developed and she died suddenly July 22, 1941 about four months after her last admission, her death having had no apparent relation to the electric shock treatments.

Necropsy findings, general. There was generalized arteriosclerosis, arteriosclerotic heart disease and mesenteric thrombosis.

Brain, gross. There was nothing abnormal except for a considerable cortical atrophy in both frontal areas, thickening of the pia-arachnoid in the frontal regions, and thickening of the vessels at the base of the brain.

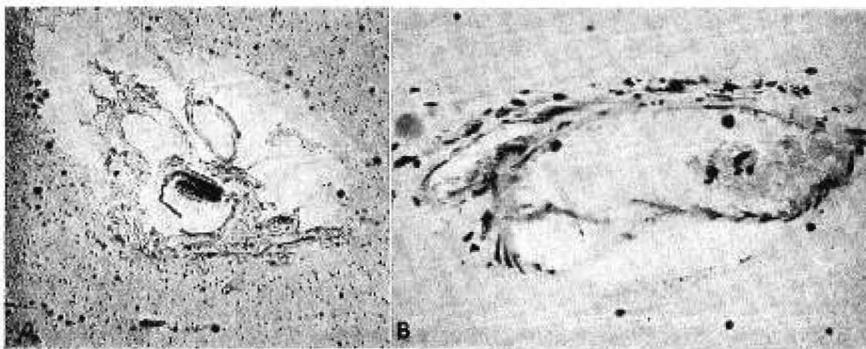


FIG. 6. (Case 2). Late effects as shown by vessels with fibrosis, perivascular edema, and collections of hyaline bodies in the adjacent brain tissue (A), and phagocytes with hemosiderin (B). Hematoxylin and eosin stain.

Microscopic anatomy. Histological study of the brain revealed a combination of fresh and old lesions. The *meninges* showed nothing abnormal except for a few scattered minute areas of fresh hemorrhage. The red cells were well preserved in these areas, indicating that the hemorrhage was probably agonal. The *cerebral cortex* showed generalized sclerosis of the arterioles throughout the cortex. The nerve cells of the cortex exhibited minor changes. Ischemic and chronic cell changes were found in parts of the cortex, and areas of focal cell loss were found here and there in the third layer of the cortex. Congestion of the vessels was seen in some parts of the cortex, and rarely was there encountered a small area of fresh perivascular hemorrhage composed of fresh red blood cells. For the most part the cerebral cortex showed little evidence of damage from electrical convulsion treatment.

In the white matter of the frontal, temporal, motor, and parietal cortex there were found numerous areas of perivascular damage. These were definitely old and consisted for the most part of dilatation of the perivascular space in which lay phagocytes containing hemosiderin pigment. These were scattered here and there in the white matter. Around some vessels there was gliosis in the adjacent white matter. In still other instances, perivascular fibrosis was present, composed of an increase of fibroblasts among which were scattered phagocytes containing hemosiderin (fig. 6). Around the dilated perivascular areas the adjacent white matter was rarefied and often showed evidence of destruction. Scattered in the white matter surrounding the affected vessels and often extending into it for some

distance were hyaline droplets or small amyloid bodies of varying size and number. Weil stains revealed no signs of perivascular demyelination.

Fresh hemorrhages were found in the brain stem. They were seen as minute perivascular hemorrhages in the tegmentum of the pons, in the floor of the medulla, and in the walls of the third ventricle. All these hemorrhages were fairly recent. The red cells were poorly preserved in most of the areas of the hemorrhage, but in no place were they completely disintegrated and no evidence of hemosiderin pigment could be seen anywhere among the hemorrhages.

Comment. The circumstances in this case differ from those noted in the preceding one, for in this instance only a few electrical convulsive treatments were given, the last treatment being administered about five months before death occurred. The brain in this case showed evidence of old and recent lesions. The punctate hemorrhages found in the brain stem must be attributed to recent agonal changes which bore no relationship to the convulsive treatment. No signs of a breakdown of the red blood cells could be found; hence it seems reasonable to assume that the hemorrhages were agonal. On the other hand, the areas of old perivascular hemorrhage, fibrosis, gliosis and rarefaction of tissue found in the white matter of the cerebrum seems traceable directly to the effects of the convulsive treatment in view of their similarity to those found in Case 1. Nor can the older perivascular changes be attributed to the cerebral arteriosclerosis which was found in the cortex, since such changes are not in our experience found in uncomplicated cerebral arteriosclerosis.

DISCUSSION

Hemorrhages in the brains of cats subjected to electrical convulsions have been described by Alpers and Hughes (1) who found evidences of subarachnoid hemorrhage and scattered punctate hemorrhages in the brain. Among thirty cats they found fourteen with subarachnoid hemorrhages and nine with brain hemorrhages. No hemorrhages were found in the medulla or the pons. Similar findings have been recorded more recently in rabbits by Weil and Heilbrunn (2). They found changes in the venous system in twenty-five out of twenty-eight rabbits subjected to electrical convulsions. Hemorrhages were found within the meninges of the brain and spinal cord and within the substance of the brain stem and spinal cord as well. The hemorrhages were confined to the immediate neighborhood of the capillaries and veins and were caused by rupture of the vessel walls.

The findings in the two herein reported cases differed in degree and to a lesser extent in location. Case 1 had sixty-two electrical convulsions during five months and died three months after the last treatment; Case 2 had six convulsive treatments, dying five months after the last treatment. In Case 1 recent perivascular hemorrhages predominated, chiefly in the cerebral cortex, white matter, pons, medulla, and basal ganglia. Areas of old perivascular hemorrhage were found in the white matter. In Case 2 no hemorrhages attributable to the convulsive treatment were seen, but in the cortical white matter there were areas of old perivascular hemorrhages similar to those seen in Case 1.

The importance of Case 1 lies in its demonstration of fresh and older hemor-

rhages both being undoubtedly the result of the electrical convulsive treatment. The significance of Case 2 is even greater than that of Case 1, for it demonstrates first of all, that damage to the brain may result from relatively few treatments and that such damage may persist for some time after the termination of treatment, five months in this case. This raises the problem whether the damage to the brain is attributable to the number and duration of the treatments. In the cats investigated by Alpers and Hughes (1) neither the number nor duration of the treatments appeared to influence the degree of damage to the brain.

The presence of evidence of old damage after electrical convulsive treatment as seen in Case 2 raises also the question whether such areas persist indefinitely and as such form foci of potential damage which may give rise to sequelae after the termination of treatment. It seems reasonable to assume that such perivascular areas in some locations are capable of giving rise to sequelae of one sort or another, especially in view of the changes found in the white matter adjacent to the vessels (gliosis, rarefaction). The clinical attitude in such instances is apt to be such as to accept the brain damage in return for immediate clinical relief, leaving the problem of sequelae to be decided by future events. That such sequelae are not improbable is shown by the brain damage reported, but whether this should deter one from use of the method is for the clinician to decide in each case until the problem of after-effects can be solved.

SUMMARY

1. Two cases treated by electrically induced convulsions are reported, Case 1 dying after sixty-two convulsive treatments, Case 2 succumbing five months after the last treatment.
2. In Case 1 fresh hemorrhages were found in the cerebral cortex, white matter, and brain stem; in Case 2 old areas of perivascular damage were found chiefly in the white matter.
3. In both instances the changes described appeared to be attributable to the convulsive treatment.
4. The possibility of sequelae resulting from the brain damage is suggested. The cooperation of the Philadelphia State Hospital is gratefully acknowledged.

BIBLIOGRAPHY

1. ALPERS, BERNARD J., AND HUGHES, JOSEPH: The Brain Changes in Electrically Induced Convulsions in Cats. *Archives of Neurology and Psychiatry*, 47: 385, 1942.
2. WEIL, ARTHUR AND HEILBRUNN, G.: Pathology of the Central Nervous System in Experimental Electric Shock. To be published in the *Archives of Neurology and Psychiatry*.